

ENDEMIC FLUOROSIS

With Particular Reference to Dental and Systemic Intoxication

AMARJIT SINGH, M.D., M.R.C.P. (Lond.)

Professor of Medicine

SUNDER J. VAZIRANI, B.D.S., D.O.S., M.S., F.I.C.D.

Professor of Oral Surgery

S. S. JOLLY, M.D.

Assistant Professor of Medicine

B. C. BANSAL, M.B.

Registrar, Central Registration

With the technical assistance of O. C. MATHUR, M.Sc.*

(Department of Medicine and Dentistry, Medical College, Patiala)

THE studies of the toxic effects of fluoride on the human system have evoked a very lively interest throughout the world because the public health programmes of fluoridation for the prevention of dental caries have always considered the risk of a remote cumulative intoxication. However, the indices of early intoxication are very poorly defined. The affinity of fluoride for the bones is acknowledged by everybody, but there is no universal agreement on its effects on other systems of the body—particularly when it has been spread over a number of years.

We have had a unique opportunity of studying the toxic potentialities of this ion because there exists an extensive belt of 'endemic fluorosis' in the southern parts of Punjab (India) mainly affecting the rural population. As already reported, people in these villages get their drinking water supply mostly from wells in which the fluorine content is high (varying from 2.5 to 14 parts per million—Singh, Jolly and Bansal, 1961; Singh and Jolly, 1961). The soil of this area is sandy and the temperature goes pretty high (116°-117° F.) in the summer.

The skeletal and neurological features of endemic fluorosis have already been described (Singh, Jolly and Bansal, 1961; Singh and Jolly, 1961; Singh, Dass, Hayreh and Jolly, 1961).

The bones, due to heavy and irregular fluoride deposition, become grotesque and markedly irregular in their contours (Figs. 1 and 2). The

sites of muscular and tendinous insertions are rendered abnormally prominent by excessive periosteal reaction with development of multiple exostoses which can be clinically palpated in many cases. The greatest changes are observed in the spine, particularly in the cervical region. The vertebræ show altered proportions and measurements in all planes, but the striking abnormality is the gross reduction of the antero-posterior diameter of the spinal canal and intervertebral foramina accounting for the neurological features of a radiculo-myelopathy. In one of our cases it was reduced to 3 mm. at the level of the third and fourth cervical vertebræ (Fig. 3). It is evident that with this degree of narrowing compression of the cord is inevitable.

The radiological features of fluorosis are characteristic and diagnostic (Møller and Gudjonsson, 1932). Sclerosis of bones is observed throughout the skeleton, with calcification of ligaments and muscular attachments.

The most pronounced changes are seen in the vertebral column with marked osteosclerosis and irregular osteophyte formation resulting in beak-like lipping and a chalky-white ground-glass appearance (Fig. 4).

The osteosclerosis and irregular calcification is evident in all the other bones of the body, particularly along the attachment of muscles and tendons in the limb bones, in the interosseous membranes and around the joint capsules (Fig. 5).

It is proposed in this paper to record some of our observations on dental fluorosis and also the systemic effects of fluorine intoxication.

* The biochemical investigations pertaining to this work were entirely carried out by Mr. Mathur.

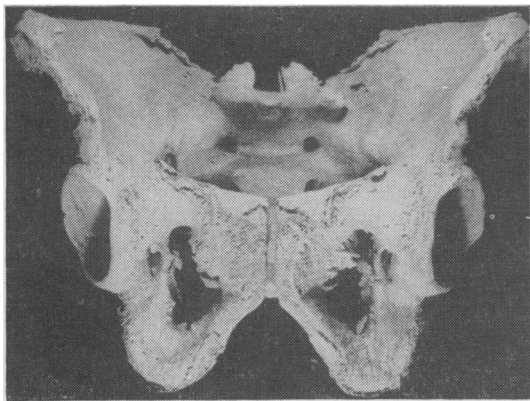


FIG. 1.—The pelvis from a case of fluorosis showing irregular bone deposition with calcification of the acetabulum.

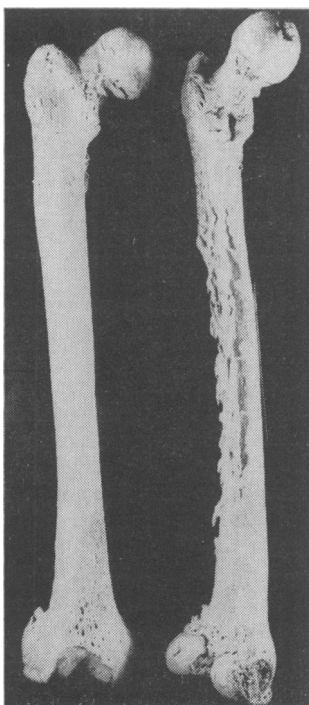


FIG. 2.—Femora from a case of fluorosis showing irregular bone deposition along the insertion of tendons.

Methods and Material

For this purpose we selected Papra, a village in the Sangrur district of Punjab, where the level of fluorine in drinking water was appreciably high (varying from 9.1 to 10.6 p.p.m.). This village has a total population of 667 individuals living in 112 houses. An effort was made to examine all the residents who were available at the time of survey. The study comprised of complete dental

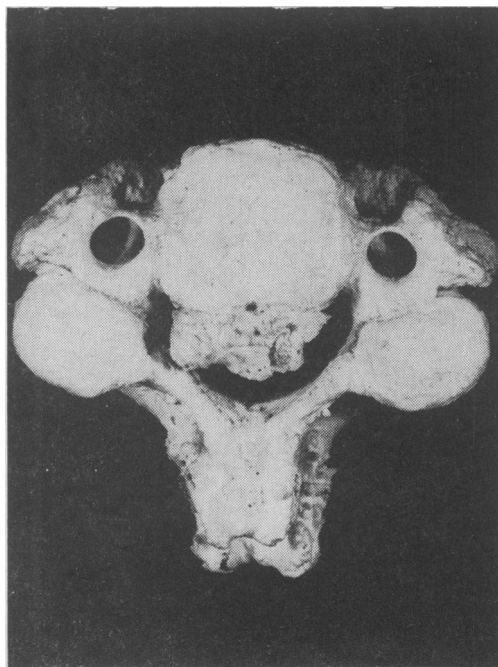


FIG. 3.—Fourth cervical vertebra from a case of fluorosis showing a huge exostosis projecting into the spinal canal thereby reducing the antero-posterior diameter to only 3 mm.

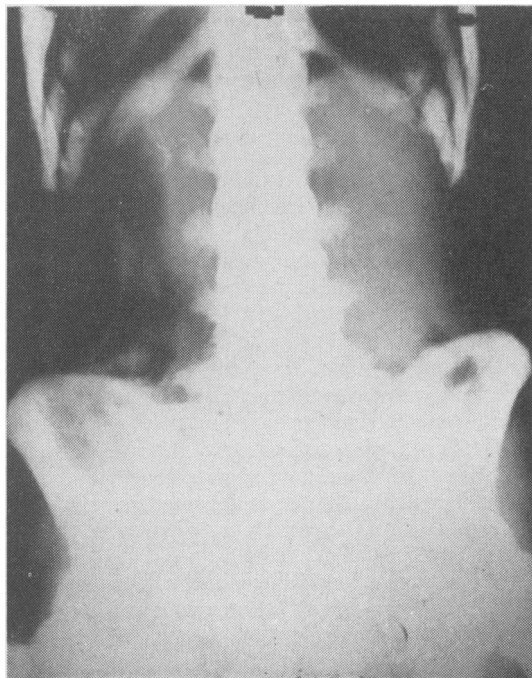


FIG. 4.—Radiograph of the lumbar spine showing osteosclerosis with calcification of inter-vertebral ligaments and irregular bone deposition in the transverse processes.

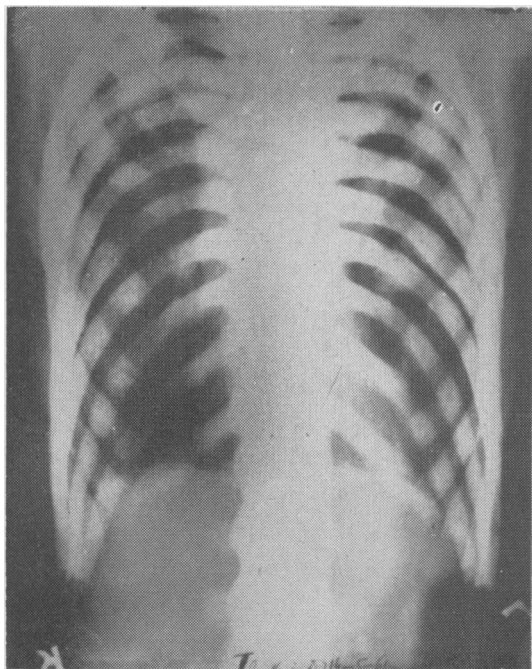


FIG. 5.—Roentgenograph of the chest showing a chalky-white bony cage in contrast to the radio-translucent lungs.

and systemic examination, roentgenographic studies of skeleton and teeth and biochemical studies, wherever indicated.

Dental Fluorosis

Mottled enamel or dental fluorosis is a well-recognized entity. It has been shown that if a person resides in an area having a fluoride content of more than 1 p.p.m. during the period of eruption of his teeth, he will most probably develop mottled enamel. On the other hand, if an individual were to move to an endemic locality after the period of development of the enamel of his teeth, there will be no mottling. Thus mottling of dental enamel has become one of the first and earliest visible signs of chronic fluorine intoxication; it is usually regarded as a sensitive diagnostic criterion and has been accepted as an index of fluorosis (Day, 1940; Dean, 1936 and 1943; McKay, 1916).

In our recent paper (Singh and others, 1961b) on skeletal fluorosis and its neurological complications, it was observed that in 25% of the 46 cases showing obvious skeletal signs of serious fluoride intoxication, there was no evidence of dental mottling even though the fluorine content of the drinking water was as much as 14 p.p.m. In view of this report, Holman (1961) questioned

the accuracy of 'mottled enamel' as an index of endemic fluorosis.

To evaluate the exact incidence of dental fluorosis and its relation to skeletal fluorosis a careful field survey of the human population was carried out in the above village where the fluorine content of the drinking water ranges from 9.12 to 10.68 p.p.m.

Results of the Present Survey

A total of 302 individuals was examined, out of which 15 were edentulous and are not included in the subsequent analysis. Of the remaining 287 persons, 170 were males and 117 females of different age-groups, as shown in Table 1.

The population was grouped into residents (257) and non-residents (30), and into those having a deciduous (49) or permanent (238) dentition. By residents we mean those persons who were born and brought up in the endemic area. Non-residents were those who either migrated as refugees or as brides into the village after the age of 14 or 15 years. Deciduous dentition age ranged from 0-5 years and permanent dentition 6 years and above.

The dental changes were grouped into three grades, and in order to standardize our study we followed the same grades as described by Siddiqui (1955):

Grade I: White opacities or patches on the enamel; very faint yellow line across the enamel.

Grade II: A distinct brown stain.

Grade III: Besides the well-established brown line, considerable pitting all over the enamel sometimes with chipped-off edges.

The population was examined with the mouth mirror and probe in the daylight.

Incidence of Mottled Enamel in Children

Forty-eight children (17.1% of the total population) in the age-group of 0-5 years were examined. They were all residents of the village. Out of these, 40 (81.6%) showed mottled enamel, whereas the remaining 9 (18.4%) had none. Out of the 40 positive cases, 80% were in grade I; 2.5% in grade II, and 17.5% in grade III dental fluorosis.

Incidence of Mottled Enamel in Adults

The permanent dentition group, i.e. aged 6 and above, consisted of 238 persons, out of which 30 were non-residents. Among 208 residents, 204 (98.1%) were suffering from mottled enamel and only 4 (4.4%) were free from dental fluorosis. The mottling was most evident on the labial surface of the upper and anterior teeth. Out of these 204 adults 19.2% were in grade I, 26.8%

in grade II, and 54% in grade III, as shown in Table I.

TABLE I
GRADING OF DENTAL PIGMENTATION

Deciduous Age 0-5 years	Total 40	Grade I 32	Grade II 1	Grade III 7
Permanent	204	39	55	110
Age Group				
6-10	50	9	9	32
11-20	56	3	11	42
21-30	38	11	15	12
31-40	27	12	9	6
41-50	16	2	8	6
51-60	12	2	3	7
61-70	5	—	—	5

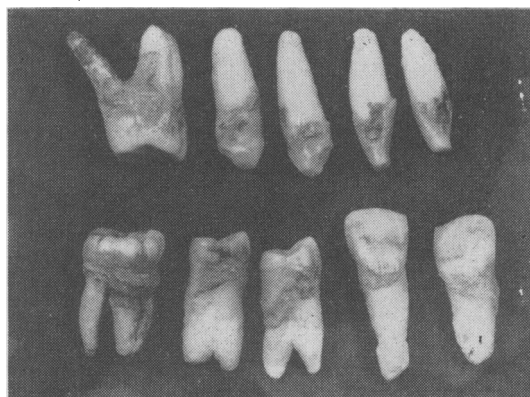


FIG. 6.—Teeth from a case of fluorosis showing irregular bone deposition near the roots of the teeth.

Incidence of Skeletal Fluorosis in Relation to Mottled Enamel

Out of the total village population only 107 individuals submitted themselves voluntarily for the whole skeleton to be radiographed. On roentgenographic evaluation 93 showed skeletal fluorosis and 14 did not. There were only 4 resident cases which did not show mottled enamel but had skeletal fluorosis (see Table 2).

Incidence of Caries

It has been observed that mottled teeth are more resistant to caries than normal teeth (Armstrong and Brekhus, 1938). From our investigation we found that out of 287 individuals surveyed, only 4 had caries (1.4% of the total population investigated).

Dental Roentgenographic Changes

During our study we came across the autopsy material of a proved fluorotic case (Singh and others, 1962). The teeth showed generalized fluorosis grade II. On gross examination the most striking change was observed in the root portion of every tooth. The root surfaces were irregular and rough and revealed heavy deposits of calcified masses in the form of excessive amounts of fluorine osteocementum at the apical region of the teeth (see Fig. 6). We have not come across

any similar published report in the dental literature on fluorosis (Stones, 1957; Thoma and Goldman, 1960). Therefore, it was decided that in the present survey we should X-ray the teeth also along with other parts of the skeleton for evidence of endemic fluorosis. The plan was to radiograph the anterior upper and lower incisors and the left and right lower molars because it was easy to angulate these areas with the portable field X-ray apparatus. For dental X-ray we used the dental cone. On a voluntary basis 86 persons submitted themselves for the dental X-ray.

As seen roentgenographically the following three features were noted, namely, osteosclerosis, cementosis, and periapical root resorption (Figs. 7 and 8).

In a typical case abnormally dense bone was noted. There was a gradual resorption of the root-apex and often the root appeared evenly resorbed, resembling in appearance post-operative apicectomy, though sometimes the resorption was irregular. Also it indicates that new bone had been deposited in the area previously occupied by the root and this was lined by a cortical layer adjoining the periodontal membrane.

Hypercementosis or cementum hyperplasia was evident on careful examination.

Out of 86 persons whose teeth were X-rayed, 68 showed osteosclerosis of the jaw bone, 41

TABLE 2
DENTAL CHANGES IN 93 CASES OF SKELETAL FLUOROSIS (63 MALE, 30 FEMALE)

	Total number of cases	Age group					
		11-20	21-30	31-40	41-50	51-60	61-70
Dental pigmentation	74	7	21	20	13	7	6
No pigmentation	19	—	—	—	—	—	—
Residents (4)	1	2	1	—	—	—
Non-residents (15)	—	7	4	1	3	—

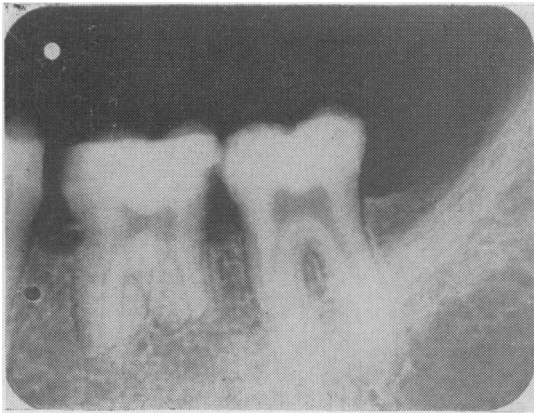

FIG. 7.—Skiagram of the teeth from a case of fluorosis showing resorption of the roots.

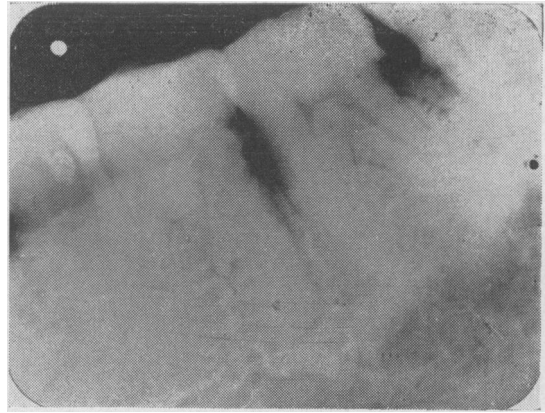


FIG. 8.—Skiagram of the teeth from a case of fluorosis showing hyper-cementosis.

showed cementosis, and in 29 cases various degrees of root resorption were recorded in the molar and incisor teeth. A higher incidence of root resorption was marked in the lower first permanent molars. Next in order of frequency were the upper lower central incisors and second molars. The early root resorption changes were detectable in age-group as early as 15-20 years. Radiological skeletal changes were noted at an age as early as 18 years.

Systemic Investigations

Sporadic reports of systemic intoxication by fluoride have been published. It is believed to lower the general nutritional status and is particularly toxic for the thyroid, kidneys and cardiovascular system. In order to detect any such systemic and visceral manifestations, we studied the village population in detail.

On general physical examination there appeared to be no evidence of under-development or undue anaemia or sign of any unusual nutritional deficiency among the people of the affected area. On the contrary, the rural population in the Bhatinda district, where the fluoride content of water is fairly high, is one of the tallest and best-built in the country. They are mostly Jat Sikhs and well known for their sturdy constitution, which is probably their racial characteristic. Similarly, there was no evidence of any sign of goitre or other thyroid disorder in the affected population. A portion of Punjab is affected by endemic goitre, but this belt extends along its north-western border along the edge of the Himalayas, while on the contrary, the fluorosis belt extends along the southern border of Punjab.

Detailed examination of the cardiovascular system, including electrocardiography, revealed

no evidence of ischaemic heart disease in the people examined. Similarly, examination of other systems was unrewarding. A plain skiagram of the urinary tract was taken in most of the cases with negative results. We have come across only one case of renal calculus out of a total of 160 X-ray positive cases of skeletal fluorosis. The urine, though normal on routine physical, chemical and microscopic examination, showed a rather characteristic change in colour on standing: it was noticed that urine on standing for 6-8 hours changed its colour to dark brown from above downwards. This gives a resemblance to the urine of cases of alkaptonuria on casual examination. Luckily a case of ochronosis with a classical clinical picture was available for comparison during the course of this study. Urine from the alkaptonuric patient when made alkaline turned black immediately on account of the conversion of homogentisic acid to melanin. The colour of the urine from the fluorotic patients, however, did not change colour immediately on addition of alkali. Further chemical tests for homogentisic acid (Harrison, 1957) were applied to these samples and also proved to be negative.

A detailed study of the urine was also made for the excretion of total nitrogen, amino-acid nitrogen, and for tyrosine and its metabolites. For this purpose 34 cases of fluorosis selected at random from our present series were examined. An increased excretion of amino acids was found in all the cases. The detailed results are tabulated in Table 3.

Discussion

Dental roentgenographic investigation features two important findings, root resorption and hypercementosis. A partial review of the litera-

TABLE 3
 TWENTY-FOUR HOURS' URINARY EXCRETION OF AMINO ACIDS IN CASES OF FLUOROSIS

	Total nitrogen (g./24 hour)	Amino acid nitrogen (mg./24 hour)	Amino N × 100	Tyrosine and its metabolites (mg. %)
			Total N	
Normal values	6—12	50—150	0.5—1.5	0—25
Mean values (fluorotic patients) ..	8.723	272.01	3.11	40.3
Range (fluorotic patients)	6.138—11.276	188.2—402.76	1.95—4.22	30.6—54.6
Standard deviations	1.254	57.77	0.6732	6.78

ture reveals no mention of the above findings in dental fluorosis (Stafne, 1959; Stones, 1957; Thoma and Goldman, 1960).

Resorption of the roots of teeth most often occurs as a result of local factors, although it may also be caused by general systemic disease. The most common local factors are trauma and pressure. Resorption that results from traumatic occlusion or from orthodontic appliances is not uncommon and is generally recognized. However, Stafne (1959) pointed out that resorption also occurs as a result of pressure exerted by impacted teeth, tumours and osteosclerosis.

As far as hypercementosis is concerned, our observation is further confirmed by recent studies by Yoon, Brudevold, Smith, Gardner and Soni (1960). It has been shown that deposition of fluorine varies, not only in different skeleton components but in different regions of the individual bones (Gardner, Smith, Hodge, Brudevold and Eldredge, 1959, Wallace, 1954; Zipkin, McClure and Leone, 1958). In view of these findings Yoon and his group (1960) studied the deposition of fluorine in different parts of alveolar bone and of the teeth. They have reported that the most notable finding in their study was the greater concentration of fluorine in the cementum than in the lamina dura and the other portions of the alveolar bone. Usually teeth so affected are asymptomatic, retain their vitality and are rarely lost as a result of the resorption. In our study no subjective symptoms were revealed in the population investigated.

Paget's disease or osteitis deformans also gives the same roentgenographic appearance as recorded in endemic dental fluorosis. As seen roentgenographically, Paget's disease shows a ground-glass appearance, evidence of resorption of the roots of the teeth and deposition of excess of cementum on the roots of the teeth.

Differential diagnosis can be established only if we examine carefully the presence of periodontal membrane and the lamina dura. The lamina dura and periodontal membrane is present in endemic dental fluorosis and absent in Paget's disease.

It will further be observed that out of 107 people X-rayed, 93 showed evidence of skeletal

fluorosis in this small village. Out of these there were four who, though residents of the place since birth, had skeletal involvement but did not have any dental mottling on most careful examination. There were 15 more cases with radiologically positive skeletal fluorosis but no dental mottling. These were, however, non-residents, having migrated to the village after the age of 14 years. This should provide some answer to the controversy started by Holman (1961) regarding the sensitivity of dental mottling as an index of fluoride intoxication in an endemic area.

In this connection there is another observation made by us that all the skeletal fluorosis cases, including 19 with no dental mottling, showed on dental X-ray, osteosclerosis, root resorption and hypercementosis. We feel that X-ray of the teeth and jaws gives an even more sensitive index of fluorosis than mere mottling of the enamel.

Sporadic reports of systemic manifestations other than skeletal and dental changes in fluorine intoxicants have been published from time to time.

Symptoms relating to general nutrition, anæmia, thyroid, skin, neuromuscular, cardiac, respiratory, gastro-intestinal and urinary systems have been reported by different workers (Waldbott, 1955, 1956, 1957, 1961; Takamori and others, 1956; Siddiqui, 1955; Silva, Chapedi and Pedace, 1940; Rao, 1955; Raffaele, 1944).

The strong affinity of fluorine for calcium is believed to interfere with calcium metabolism. Its affinity for other metals, especially magnesium and manganese, has been accounted for by its interference with certain enzymes.

In our series, however, we failed to come across any such visceral or systemic manifestation except the change in the colour of the urine on standing. This has also been reported by Pandit and Rao (1940) in experimental fluorosis in monkeys. They suggested that this may be due to the excretion of homogentisic acid and metabolites of tyrosine. Our studies, however, show that the chemical present in the urine which is responsible for the change of colour is not homogentisic acid but some other metabolite of tyrosine as indicated by the increase in 24 hours' urinary excretion of

tyrosine derivatives. Further, our observations of increased excretion of total amino-acids in the urine in fluorosis cases also indicates that fluorides are probably excreted in organic molecular form in combination with amino-acids. We are carrying out further work on experimental animals to confirm our preliminary observations. It is also possible that the absence of visceral toxic effects in endemic fluorosis may be due to this mechanism of excretion. Damage to the kidney and other organs in experimental fluorosis is well known. The absence of such manifestation in endemic fluorosis may be due to the gradual detoxication and excretion of fluorides by the conversion into this organic molecular form in combination with amino-acids. Our observations that skeletal fluorosis is more common among the poor in the endemic area may also be thus explained because of the lesser amount of amino-acids available for excretion in poor and under-nourished people. It is also possible that the pigment in mottled teeth may be of the same nature as that excreted in the urine, viz. some metabolite of tyrosine. This, however, needs confirmation.

Finally it will be interesting to point out the preventive measures that are being adopted in the

endemic area. In the village of Papra, to which the present report relates, deep drilling at one place at a depth of 250 feet has yielded water containing only 1 p.p.m. of fluorine, as compared to about 9-10 p.p.m. in ten superficial wells, which were so far the source of drinking water. In the other villages, canal water after due purification is being utilized because its fluorine content has been found to be only 0-5 p.p.m.

Summary

A careful survey of an isolated community in an endemic fluorosis area has been carried out specially to evaluate the relative incidence of dental fluorosis compared to skeletal fluorosis with the following observations:—

(1) Dental mottling, although a very sensitive index, may be absent in a small number of skeletal-positive cases.

(2) Some useful radiological features of dental fluorosis have been revealed.

(3) Biochemical examination of the urine in cases of fluorosis has given some interesting clues to further studies in the mode of fluoride excretion.

(4) The absence of any other manifestation of toxic systemic effects is stressed.

REFERENCES

- ARMSTRONG, W. D., and BREKHUS, P. J. (1938): Relationship of Fluorine Content of Enamel and Resistance to Dental Decay, *J. dent. Res.*, **17**, 301.
- DAY, C. D. M. (1940): Chronic Endemic Fluorosis in Northern India, *Brit. Dent. J.*, **68**, 409.
- DEAN, H. T. (1936): Chronic Endemic Dental Fluorosis (Mottled Enamel), *J. Amer. med. Ass.*, **107**, 1269.
- , and ARNOLD, F. A. (1943): Endemic Dental Fluorosis or Mottled Teeth, *Ibid.*, **30**, 1278.
- GARDNER, D. E., SMITH, F. A., HODGE, H. C., BRUDEVOID, F., and ELDRIDGE, D. M. (1959): Distribution of Fluoride in the Normal Dog Femur, *J. Appl. Physiol.*, **14**, 427.
- HARRISON, G. (1957): Chemical Methods in Clinical Medicine, p. 252. London: J. A. Churchill & Co.
- HOLMAN, R., WILSON, D. C., and GRIFFITH, G. W. (1961): Skeletal Fluorosis, *Lancet*, **i**, 399, 449, 506.
- MCKAY, F. S., and BLACK, G. V. (1916): Mottled Teeth, *Dental Cosmos.*, **58**, 129.
- PANDIT, C. G., and RAO, D. N. (1940): Endemic Fluorosis in India—Experimental Production of Fluorine Intoxication in Monkeys (*Macca Radiata*), *Indian J. med. Res.*, **28**, 559.
- RAFFAELE, J. F. (1944): La Fluorosis. Buenos Aires: El Atenco.
- RAO, S. V. (1955): Fluorosis Causing Paraplegia, *J. Indian med. Prof.*, **2**, 780.
- SIDDQUI, A. H. (1955): Fluorosis in Nalgonda District, Hyderabad-Deccan, *Brit. med. J.*, **ii**, 1408-1413.
- SILVA, L. L., CHAPEDI, E., and PEDACE, E. A. (1940): Fluorosis and Tuberculosis, *Sem. méd. (B. Aires)*, **47**, 1413-1434.
- SINGH, A., JOLLY, S. S., and BANSAL, B. C. (1961a): Skeletal Fluorosis and its Neurological Complications, *Lancet*, **i**, 197.
- , — (1961b): Endemic Fluorosis with Particular Reference to Fluorotic Radiculo-Myelopathy, *Quart. J. Med. N.S.*, **30**, 357.
- , DASS, R., HAYREH, S. S., and JOLLY, S. S. (1962): Anthropometric Measurements in a Case of Fluorosis. In the press.
- STAFNE, E. C. (1959): Oral Roentgenographic Diagnosis, pp. 111-113. Philadelphia: W. B. Saunders.
- STONES, H. H. (1957): Oral and Dental Diseases, pp. 125-182. London: E. & S. Livingstone.
- TAKAMORI, T. (1955): Recent Studies on Fluorosis-Jokushima, *J. exp. Med.*, **2**, 25.
- THOMA, K. H., and GOLDMAN, H. M. (1960): Oral Pathology, pp. 103-110. St. Louis: C. V. Mosby
- WALDBOTT, G. L. (1955): Chronic Fluorine Intoxication from Drinking Water, *Int. Arch. Allergy*, **7**, 70.
- (1956): Incipient Fluoride Intoxication from Drinking Water, *Acta med. Scand.*, **156**, 157.
- (1957): Tetaniform Convulsions Precipitated by Fluoridated Drinking Water, *Confin. neurol. (Basel)*, **17**, 339.
- (1961): The Physiologic and Hygienic Aspects of Absorption of Inorganic Fluorides, *Arch. Environmental Health*, **2**, 59-155.
- WALLACE-DURBIN, P. (1954): The Metabolism of Fluorine in the Rat Using F 18 as a Tracer, *J. dent. Res.*, **33**, 789.
- YOON, S. H., BRUDEVOID, F., SMITH, F. A., GARDNER, D. E., and SONI, N. (1960): Distribution of Fluorine in Teeth and Alveolar Bone, *J. Amer. dent. Ass.*, **61**, 565.
- ZIPKIN, I., MCCLURE, F. J., and LEONE, M. C. (1958): Fluoride Deposition in Human Bones After Prolonged Ingestion of Fluoride in Drinking Water, *Publ. Hlth Rep. (Wash.)*, **73**, 732.